

**SETTLEMENT DEMAND**

**DATE:**

**Addressee:**

XXXX  
987-654-3210 Ext. 1234567  
XXXX Insurance Company

Re:       **My Client:**                   Patient Name  
          **Your Insured:**  
          **Claim Number:**           0987654XXXX  
          **Incident Date:**       November 2, YYYY

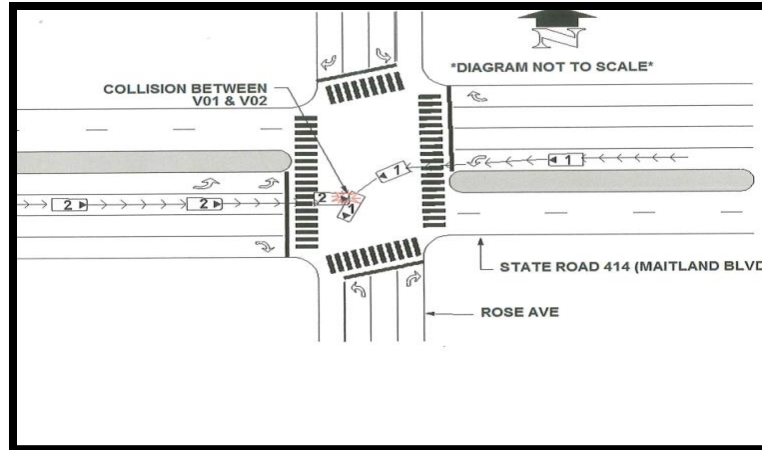
Dear XXXX:

Please consider this correspondence as my client's demand for the full and final resolution of the above referenced claim.

**FACTS AND LIABILITY**

On November 2, YYYY, at 3:30 pm, XXXX, was the properly restrained front seat passenger of a YYYY Toyota Camry, which was being driven by XXXX. They were traveling eastbound in the left turn lane of State Road 414 (Mainland Boulevard) City of \_\_\_\_\_, Florida. Your insured XXXX was driving his 2013 Honda Accord, westbound in the left side lane. When Ms. XXXX vehicle proceeded through the intersection of \_\_\_\_\_, Mr. XXXX disregarded the red signal and made an abrupt left turn onto \_\_\_\_\_. Consequently, Ms. XXXX vehicle's front end collided with the right rear of Mr. XXXX vehicle.

A Traffic Collision Report was prepared by Florida Highway Patrol, which determined that Mr. XXXX caused this collision by violating section 316.075 (1)(c)1, failed to stop at steady red signal. *(Exhibit-1)*



### PROPERTY DAMAGE

As a result of the collision on November 2, YYYY, the YYYY Toyota Camry that Ms. XXXX was traveling sustained disabling damage to its front end and was towed by Cortes Towing. The vehicle damage was estimated to be \$15000.00.

### SUMMARY OF PHYSICAL INJURIES

As a result of the collision, Ms. XXXX, a 00-year-old woman, sustained the following injuries:

- *G44.309* **Post traumatic cervicogenic headaches**
- *M50.021* **Cervical disc disorder at C4-C5 level with myelopathy**
- *M50.121* **Cervical disc disorder at C4-C5 level with radiculopathy**
- *M99.51* **Intervertebral disc stenosis of neural canal of cervical region**
- *M51.26* **L5-S1 herniated disc**
- *M51.16* **Intervertebral disc disorders with radiculopathy in lumbosacral region**
- *M50.222* **Cervical disc displacement at C5-C6 level**
- *M99.53* **Intervertebral disc stenosis of neural canal of lumbar region**
- *M40.03* **Postural kyphosis, cervicothoracic region**
- *S13.0XXD* **Traumatic rupture of cervical intervertebral disc**
- *M50.123* **Cervical disc disorder at C6-C7 level with radiculopathy**
- *M50.023* **Cervical disc disorder at C6-C7 level with myelopathy**
- *M99.01* **Segmental and somatic dysfunction of cervical spine**
- *M99.02* **Segmental and somatic dysfunction of thoracic spine**
- *M99.03* **Segmental and somatic dysfunction of lumbar spine**
- *M99.04* **Segmental and somatic dysfunction of sacral spine**
- *M99.06* **Segmental and somatic dysfunction of bilateral lower extremities**
- *M99.07* **Segmental and somatic dysfunction of bilateral upper extremities**
- *M54.12* **Bilateral cervical radiculitis**
- *M54.16* **Bilateral lumbar radiculitis**
- *S20.219A* **Contusion of chest wall**
- *S90.31XA* **Contusion of right foot**

- *S70.01XA*            **Contusion of right hip**
- *S70.02XA*            **Contusion of left hip**
- *S80.01XA*            **Contusion of right knee**
- *S13.4XXA*           **Sprain/strain of cervical spine**
- *S23.3XXA*           **Sprain/strain of thoracic spine**
- *S33.5XXA*           **Sprain/strain of lumbar spine**
- *R07.9*                **Pain in her chest**
- *M79.671*            **Pain in right foot**
- *M54.2*                **Cervicalgia**
- *M54.40*             **Lumbago**

### **TREATMENT OF INJURIES**

Following the collision on November 2, YYYY, the paramedics of Fire Orange Rescue County Department (*Exhibit-2*) arrived at the scene and examined Ms. XXXX. She complained of pain in her left upper arm and right foot and stiffness in her neck. A physical examination and vital signs were obtained. Her neck was immobilized with a cervical collar. An electrocardiogram was obtained which revealed sinus tachycardia. ECG was monitored throughout her transportation to the hospital. She was then transported to the Emergency Department of XXXX for further evaluation and care.

Subsequently, Ms. XXXX was examined by XXXX, PA-C., and XXXX, D.O., in the Emergency Department of XXXX (*Exhibit-3*) for the complaints of pain in her left arm, neck and right foot. She reported her pain level as 9/10 in her right foot. She stated that she hit right side of her head on the door. She had tingling sensation in her bilateral lower extremity. She was tearful/ crying and anxious. A physical examination revealed tenderness over her neck, hips, and right foot. She had abrasions in her left upper arm and right foot. X-rays of her hips with pelvis, thoracic spine, right foot, right ankle and CTs of her head and chest were obtained and reviewed. An electrocardiogram and Laboratory test were obtained and reviewed. The CT of her chest revealed reversal of the normal cervical lordosis, which was likely due to muscle spasm. The X-ray of her right foot and right ankle revealed soft tissue swelling. Zofran, Ketorolac, and Morphine were administered intravenously. She was diagnosed with contusion of chest wall, right foot, and hips, and pain in her chest. The cervical collar in her neck was removed. Lidoderm Patch, Robaxin, and Ibuprofen were prescribed. She was recommended to follow up with her primary care physician in one to two days. She was discharged from the facility.

On November 7, YYYY, Ms. XXXX had an initial chiropractic treatment evaluation with XXXX, D.C., at XXXX Healthcare (*Exhibit-4*) for the complaints of pain in her neck, mid-back, lower back, hip and right foot. She also complained of stiffness in her neck as well as pain in her knees, bilateral foot and toes. Her neck pain radiated to her left shoulder, right shoulder, arms, elbows, wrists and hands and fingers. She quantified her pain level as 9/10. The pain in her left shoulder worsened with lifting objects and right shoulder, upper back, and mid-back and lower back pain worsened with standing, sitting, lifting, bending, navigating stairs and changing positions.

On examination she had fixation in her cervical spine, thoracic spine and lumbosacral spine and tenderness over her shoulders, knees, and feet. She was noted to have spasm and hypertonicity in her shoulders, cervical spine, thoracic spine, and lower back and trigger points in her bilateral supraspinatus, infraspinatus, and suboccipital. She was noted to have edema in her left arm and right foot. She was noted to have limping gait when ambulating. Orthopedic test such as bilateral maximal foraminal compression test, Jackson's test, shoulder depression test, Soto-hall test, Apley scratch test, right side straight leg raise test, Fajersztajn's test, Braggard's test, Bechterew's test and bilateral Kemp's test were all positive. Her postural analysis revealed anterior head translation. The range of motion of her cervical spine and lumbar spine were limited due to pain, spasm and guarded muscle. She was noted to have limited range of motion in her knees and shoulder due to pain, spasm and guarded muscle. She had decreased strength in her cervical spine, and hypoesthesia in her cervical spine and lumbar spine. She was noted to have bruising on her left upper arm, right foot, and right ankle.

She was diagnosed with sprain/strain of cervical spine, thoracic spine and lumbar spine, strain of wall of thorax, shoulders, contracture of right knee, pain in knees, contusion of right knee, pain in feet, and segmental and somatic dysfunction of cervical region, thoracic region, lumbar region, sacral region, bilateral lower extremity and upper extremity, contracture of muscles and secondary kyphosis of cervical region. She was recommended to have an Emergency Medical Condition evaluation and MRIs of her cervical spine and lumbar spine. The treatment was comprised of application of cold pack, electrical stimulation, and mechanical traction. She was advised to continue receiving chiropractic treatment.

On November 15, YYYY, Ms. XXXX had MRI of her cervical spine and lumbar spine at Stand-up MRI of XXXX upright MRI (*Exhibit-5*). The MRI of her cervical spine revealed loss of normal cervical lordosis and straightening of normal cervical lordotic curvature with muscle spasm due to ligamentous sprain and disc injury. There was edema associated with the apical ligament with ligamentous sprain due to whiplash injury. There was an interval development of a focal central disc herniation and impingement of the ventral thecal sac at C3-C4 levels. There was a focal extruded disc herniation with edema in the annular fibers. In addition, at C4-C5 level: there was ligament impingement on the ventral thecal sac. There was a flattening of the thecal sac and cervical cord. There was annular tearing, which indicated annular rupture and edema that was related to acute and sub-acute. There was an interval worsening of broad-based disc herniation eccentric to the right. There was impingement on the ventral thecal sac with flattening of the cervical cord. The disc herniation encroached upon the exiting right C7 nerve root. The MRI of her lumbar spine revealed disc bulge with herniation at L5-S1 levels.

On December 5, YYYY, Ms. XXXX presented to XXXX, M.D., at Care Now Urgent Care (*Exhibit-6*) for the complaints of pain in her neck, mid-back and lower back and right mid-foot. She had muscle pain. A physical examination revealed tenderness and painful range of motion in her neck and lower back and pain on palpation in her right mid-foot. She was diagnosed with sprain of cervical spine, lumbar spine and pelvis, strain of back of wall of thorax and contusion of right foot. Cyclobenzaprine was prescribed. Dr. XXXX opined that Ms. XXXX had met criteria for an Emergency Medical Condition determination. She was recommended to receive aggressive physical therapy and continue receiving chiropractic treatment with Dr. XXXX as well as follow up in three days.

On January 9, YYYY, Ms. XXXX presented to XXXX, M.D., at Advanced Orthopedics and

Spine Surgery (*Exhibit-7*) for the complaints of pain in her neck, lower back, and right knee and right foot. She reported her pain level as 8/10. She also had headaches daily, which exacerbated her migraine. Her neck pain worsened with bending and side bending. She had numbness and tingling radiated to her arms and hands. The pain in her lower back radiated to her left knee, and left leg. She had radicular pain in her toes and tingling sensation in her right toes. Her lower back pain exacerbated with sitting and walking for a prolonged period of time.

A physical examination revealed restricted range of motion and tenderness over her cervical spine and lumbosacral spine. Spurling's test was positive. She had radicular pain at C6-C7 dermatomal distribution. She had decreased sensation in her C7 dermatomal distribution. The MRI of her cervical spine and lumbar spine dated November 15, YYYY were reviewed. She was diagnosed with cervicalgia, C3-C4 focal central herniated disc, C4-C5 extruded disc with cranial migration, C6-C7 broad herniated disc eccentric to the right with exiting right C7 nerve root impingement and flattening the cervical cord, bilateral cervical radiculitis, post traumatic cervicogenic headaches, post traumatic cervical facet syndrome, lumbago, L5-S1 herniated disc, post traumatic lumbar facet syndrome, and bilateral lumbar radiculitis. Dr. XXXX stated the above-mentioned injuries were the direct result of the collision that occurred on November 2, YYYY. She was recommended to have a consultation with Dr. XXXX. Treatment option included cervical and lumbar epidural injection, however, no treatment could be provided as she was pregnant at that time. Dr. XXXX opined that, Ms. XXXX had met the criteria for the emergency medical condition determination due to her physical condition. She experienced intense pain, which resulted in permanent impairment of her bodily function or parts. Therefore, she would require immediate or ongoing treatment to prevent the worsening of her symptoms.

On January 10, YYYY, Ms. XXXX presented to XXXX, M.D., at Advanced Orthopedics and Spine Surgery for the complaints of headaches and pain in her neck. She reported her pain level as 8/10. A physical examination revealed painful range of motion in her neck. She had discomfort and axial compression of the head and neck. She was noted to have myospasm in her cervical muscles and trapezii. She was diagnosed with herniated nucleus pulposus at C3-C4, C4-C5 and C6-C7 levels, annular tear at C5-C6 levels. Dr. XXXX opined that treatment could not be provided as she was six months pregnant at that time of evaluation. She was recommended to undergo anterior cervical discectomy fusion at C4-C5 and C5-C6 levels after her post-partum period.

From November 11, YYYY through March 10, YYYY, Ms. XXXX received chiropractic treatment from Dr. XXXX at XXXX Healthcare for the complaints of pain in her neck, mid-back, upper back, lower back, hip and right foot and stiffness in her neck as well as pain in her knees, bilateral foot and toes. The treatment was comprised of chiropractic manipulative therapy, extraspinal chiropractic manipulative therapy, mechanical traction, therapeutic exercise, neuromuscular re-education, and manual therapy. 173-344

On March 12, YYYY, Ms. XXXX had her final chiropractic treatment from Dr. XXXX at XXXX Healthcare for the complaints of pain in her neck, upper back, mid-back, lower back, hip and right foot and stiffness in her neck as well as pain in her knees, bilateral foot and toes. On examination, she had tenderness over her cervical spine, shoulders, thoracic spine, and lumbar spine as well as right knee. She was noted to have spasm and hypertonicity in her cervical spine, shoulders, thoracic spine, and lumbar

spine. There were trigger points in her supraspinatus, infraspinatus and suboccipital regions. She had edema in her right foot and left arm. Her gait was noted to be visual limp. Orthopedic test such as bilateral maximal foraminal compression test, Jackson's test, shoulder depression test, Soto-hall test, Apley scratch test, right side straight leg raise test, Fajersztajn's test, Braggard's test, Bechterew's test and bilateral Kemp's test were positive. Her postural analysis revealed anterior head translation. The range of motion of her cervical spine and lumbar spine were limited due to pain, spasm and guarded muscle. She was noted to have limited range of motion in her knees and shoulder due to pain, spasm and guarded muscle. She had decreased strength in her cervical spine, and hypoesthesia in her cervical spine and lumbar spine. She was noted to have bruising on her left upper arm, right foot, and right ankle.

She was diagnosed with sprain/strain of cervical spine, thoracic spine and lumbar spine, strain of wall of thorax, shoulders, contracture of right knee, pain in knees, contusion of right knee, pain in feet, and segmental and somatic dysfunction of cervical region, thoracic region, lumbar region, sacral region, bilateral lower extremity and upper extremity, cervical disc disorder at C4-C5 level with myelopathy, intervertebral disc stenosis of neural canal of cervical region, cervical disc disorder at C4-C5 level with radiculopathy, contracture of right knee, intervertebral disc disorders with radiculopathy, lumbosacral region, other cervical disc displacement at C5-C6 level, intervertebral disc stenosis of neural canal of lumbar region, postural kyphosis, cervicothoracic region, traumatic rupture of cervical intervertebral disc, cervical disc disorder at C6-C7 level with radiculopathy, and cervical disc disorder at C6-C7 level with myelopathy and contracture of muscles multiple sites. She received chiropractic manipulative therapy, extraspinal chiropractic manipulative therapy, mechanical traction, therapeutic exercise, neuromuscular re-education, and manual therapy. She was recommended to continue receiving rehabilitation.

#### **MEDICAL EXPENSES**

The medical expenses (*Exhibit-8*) for the treatment of injuries that Ms. XXXX suffered because of the collision amounted to **\$52,955.02**. Copies of the medical bills are attached and itemized below:

<b>XXXX Fire Rescue</b>	<b>:</b>	<b>\$991.00</b>
<b>XXXX Health</b>	<b>:</b>	<b>\$30,194.76</b>
<b>XXXX MRI</b>	<b>:</b>	<b>\$9,600.00</b>
<b>XXXX Care</b>	<b>:</b>	<b>\$246.00</b>
<b>XXXX and Spine Surgery</b>	<b>:</b>	<b>\$653.00</b>
<b>XXXX Care</b>	<b>:</b>	<b><u>\$11,270.26</u></b>
<b>Total Medical Expenses</b>	<b>:</b>	<b>\$52,955.02</b>

#### **FUTURE MEDICAL EXPENSES**

Ms. XXXX will require orthopedics follow-up for evaluation of her neck, mid-back, upper back, lower back, and shoulders, and lower extremities. She will require a neurologist consultation and an EMG/NCV of her bilateral upper extremity to rule out her radicular symptoms. As recommended by Dr.

XXXX, she will require a series of cervical and lumbar epidural cortisone injections for her neck and lower back pain. Dr. XXXX also suggested that, if she fails to improve after receiving conservative treatment, she would require an anterior cervical discectomy fusion surgery at her C4-C5 and C5-C6 levels after her post-partum period. She will also require additional chiropractic treatment to strengthen her muscle and increased range of motion in her affected area. She will require pain management for control of any narcotics, muscle relaxants, NSAIDs and possible epidural steroid injections. Radiological diagnostic tests such as an MRI of head, neck, and back may also have to be obtained in the future to aid in precise evaluation. The approximate estimates of her medical expenses in the future are as follows:

<b>Orthopedics consultation</b>	:	<b>\$3,600.00- \$4,800.00</b>
<b>Neurologist consultation</b>	:	<b>\$1,600.00- \$2,000.00</b>
<b>EMG/NCV of bilateral upper extremity</b>	:	<b>\$1,200.00- \$1,800.00</b>
<b>Cervical epidural steroid injections</b>	:	<b>\$3,600.00- \$4,950.00</b>
<b>Lumbar epidural steroid injections</b>	:	<b>\$3,750.00- \$5,250.00</b>
<b>Anterior cervical discectomy fusion at C4-C5 and C5-C6 levels</b>	:	<b>\$55,000.00-\$65,000.00</b>
<b>Additional chiropractic sessions</b>	:	<b>\$2,400.00- \$3,000.00</b>
<b>MRI of head, neck, and back</b>	:	<b>\$7,000.00-\$8,000.00</b>
<b>Pain management consultation</b>	:	<b>\$1,500.00- \$2,000.00</b>
<b>Medications</b>	:	<b><u>\$1,000.00- \$1,400.00</u></b>
<b>Total Future Medical Expenses</b>	:	<b>\$80,650.00-98,200.00</b>

### LIFESTYLE IMPACT

Ms. XXXX is a 00-year-old woman with an average life expectancy of approximately another 50 years. She continues to suffer from headaches and pain in her neck and low back as a result of the collision on November 2, YYYY. The pain in her low back aggravates with sitting, standing, and walking. She experiences dizziness because of her constant headaches. Due to her pregnancy, she has been unable to receive any treatment for her injuries, which she experiences as a result of the collision. Consequently, she has been forced to live with the pain until the birth of her child. She suffers from insomnia and inability to fall asleep and stay asleep. She reports difficulty concentrating, and feels a sense of restlessness. The pain in her neck exacerbates with movements, sleeping, lying down, and sitting for prolonged periods. The headaches and sleep disturbances makes her irritable. She has lost her enjoyment and joyful mood. She is not able to perform domestic activities such as dishwashing, vacuuming, cleaning, and preparing meals. She has become depressed and angry, had difficulty sleeping, and experienced significant loss of appetite. All of these problems are directly related to the accident, and she is entitled to compensation for mental pain and suffering due to the collision.

Despite receiving multiple medical interventions, her pain is undiminished. As a result, she will face limitations in all areas of her life for a significant duration of her life. She continues to face severe hardships and is unable to lead a normal and restriction free life without pain and suffering. She is likely to remain hampered for a significant time in the future for which she must be rightfully compensated.

**SUMMARY OF DAMAGES**

<b>Medical expenses</b>	<b>:</b>	<b>\$52,955.02</b>
<b>Future medical expenses</b>	<b>:</b>	<b>\$80,650.00-\$98,200.00</b>
<b>Future loss of income</b>	<b>:</b>	<b>Unknown at this time</b>
<b>Lifestyle impact/loss of activities</b>	<b>:</b>	<b>\$</b>

**CONCLUSION**

We recognize that your insured maintained only [REDACTED] in available liability coverage to respond to this incident. In the spirit of compromise and in an effort to resolve this matter without the time and expense necessarily involved in formal litigation, I have been authorized by my client to demand settlement in the amount of [REDACTED] from this policy, **if you tender this amount and the settlement check and Release are received in my office on or before [REDACTED]**. If this amount exceeds your insured's available policy limits, please consider this a policy limits demand. Acceptance of the policy limits is conditioned upon a receipt of a certified copy of the policy declarations page. Please be advised that if settlement cannot be accomplished in accordance with the terms as set forth, I have been instructed to file a lawsuit against your insured, and I feel confident that we will receive a verdict in excess of your insured's policy limits and will then be forced to commence unpleasant collection activities directly from your insured.

This demand for settlement is subject to verification of no excess coverage and permission from the UM carrier to accept same.

I trust that your reasonable evaluation of this file will lead to a settlement and you will not subject your insured to the litigation process. Copies of my client's relevant medical records and Bills Are Enclosed.

This letter is intended for settlement purposes only and shall not be deemed admissible pursuant to § [REDACTED], Florida Statutes.

Sincerely,

Enclosure  
cc:



**EXHIBITS**

- |                  |          |   |
|------------------|----------|---|
| <b>Exhibit-1</b> | <b>:</b> | <b>Traffic Collision Report</b>               |
| <b>Exhibit-2</b> | <b>:</b> | <b>XXXX County Department</b>                 |
| <b>Exhibit-3</b> | <b>:</b> | <b>XXXX Health</b>                            |
| <b>Exhibit-4</b> | <b>:</b> | <b>XXXX Healthcare</b>                        |
| <b>Exhibit-5</b> | <b>:</b> | <b>XXXX upright MRI</b>                       |
| <b>Exhibit-6</b> | <b>:</b> | <b>XXXX Care</b>                              |
| <b>Exhibit-7</b> | <b>:</b> | <b>Advanced Orthopedics and Spine Surgery</b> |
| <b>Exhibit-8</b> | <b>:</b> | <b>Medical Expenses</b>                       |

Medico Legal Request LLC